

**Arterial Lower Limb Duplex**Examined **11/01/2019 09:42**

Page 1 of 2

Kiran Joseph

Reference

Accession **CR-19-0001942**

Patient **Patricia Goodwin**
D.O.B. **07/03/1935**

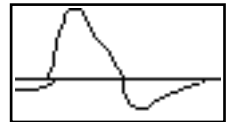
NHS No **438 963 5530**
Patient Ref **3098336**

Reason Rest pain

Outcome Stenosis mild, Stenosis moderate, Stenosis severe, Occlusion

Right**Left****Brachial****Common Femoral**

Good

**High Thigh****Low Thigh****Popliteal**

Absent

High Calf**Peroneal****Anterior Tibial**

Reduced

Posterior Tibial

Weak

Dorsalis Pedis**Toe Pressure****Post Exercise****Notes****BILATERAL LOWER LIMB ARTERIAL DUPLEX:**

Aorta - partially obscured, however aneurysmal where seen, maximum outer to outer L.S plane diameter of 2.7cm.

RIGHT:

CFA - turbulent flows and raised velocities, suggestive of a moderate stenosis, PSV 338cm/s.

PFA origin - patent with turbulent biphasic waveforms, PSV 259cm/s.

Assessed by **Sharifa Kiyegga**

Printed on 30/01/2019 at 5:48 pm

Checked by _____

**Kiran Joseph**

Reference

Accession **CR-19-0001942**

Patient **Patricia Goodwin**
D.O.B. **07/03/1935**

NHS No **438 963 5530**
Patient Ref **3098336**

SFA - patent with multi-segment stenoses ranging from mild to moderate/ severe in the proximal to mid thigh vessel. Distal vessel thigh SFA is patent with slightly reduced monophasic waveforms, PSV 125cm/s. PopA - appears occluded with echolucent material ?thrombus, which extends to the TPT.

TPT appears occluded.

ATA - patent at the ankle, slightly reduced monophasic waveforms, PSV long length, triphasic waveforms at the ankle, 68cm/s.

PTA - occluded at the ankle.

LEFT:

CFA - patent with biphasic waveforms, PSV 116cm/s.

PFA origin - patent with triphasic flow, PSV 204cm/s.

SFA - vessel origin/prox vessel is patent but is severely diseased with mixed echogenic ?thrombus, which becomes occlusive in the proximal vessel. SFA remains occluded to the mid popliteal artery.

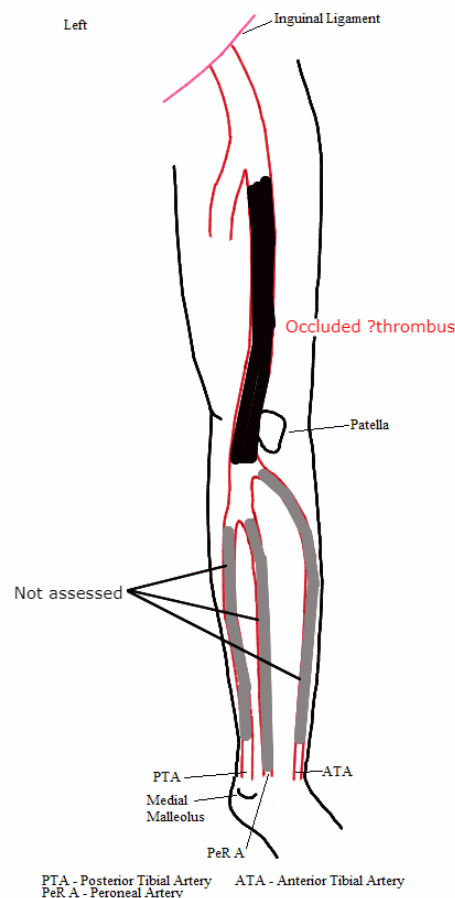
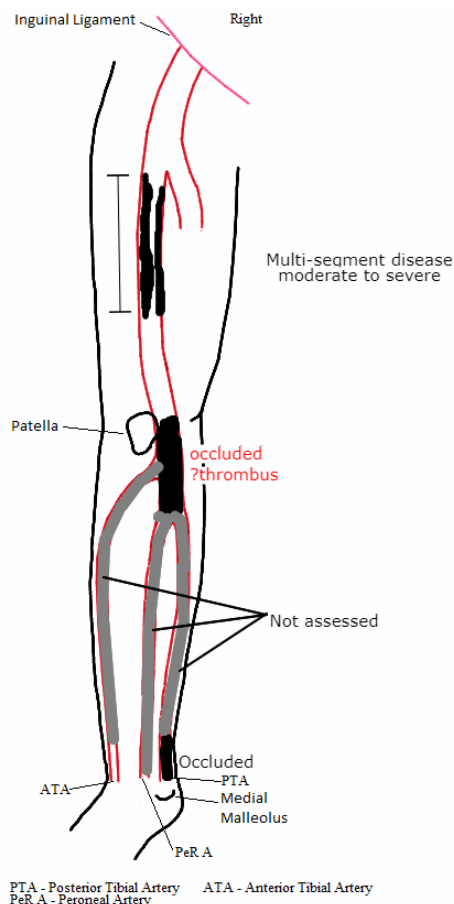
PopA - proximal vessel appears occluded with mixed echogenic thrombus ?thrombus. Mid to distal vessel is patent with moderate disease.

TPT is patent with moderate disease.

ATA and PTA - patent at the ankle, reduced monophasic waveforms at the ankle, PSV 24-38cm/s.

Bilateral resting ABPI's not performed due to acute nature of disease.

SUGGEST URGENT VASCULAR OPINION IF APPROPRIATE.



Assessed by **Sharifa Kiyegga**

Printed on 30/01/2019 at 5:48 pm

Checked by _____